

# Hypertensive Hypervolemic Vasodilatory (HHVD) Therapy with Intravenous Nicardipine for the Treatment of Cerebral Vasospasm



Benjamin Emanuel, DO  
Monica Sapo, BS  
Dave McArthur, PhD, MPH  
Paul M. Vespa, MD, FCCM  
Department of Neurosurgery  
UCLA/Ronald Reagan Medical Center

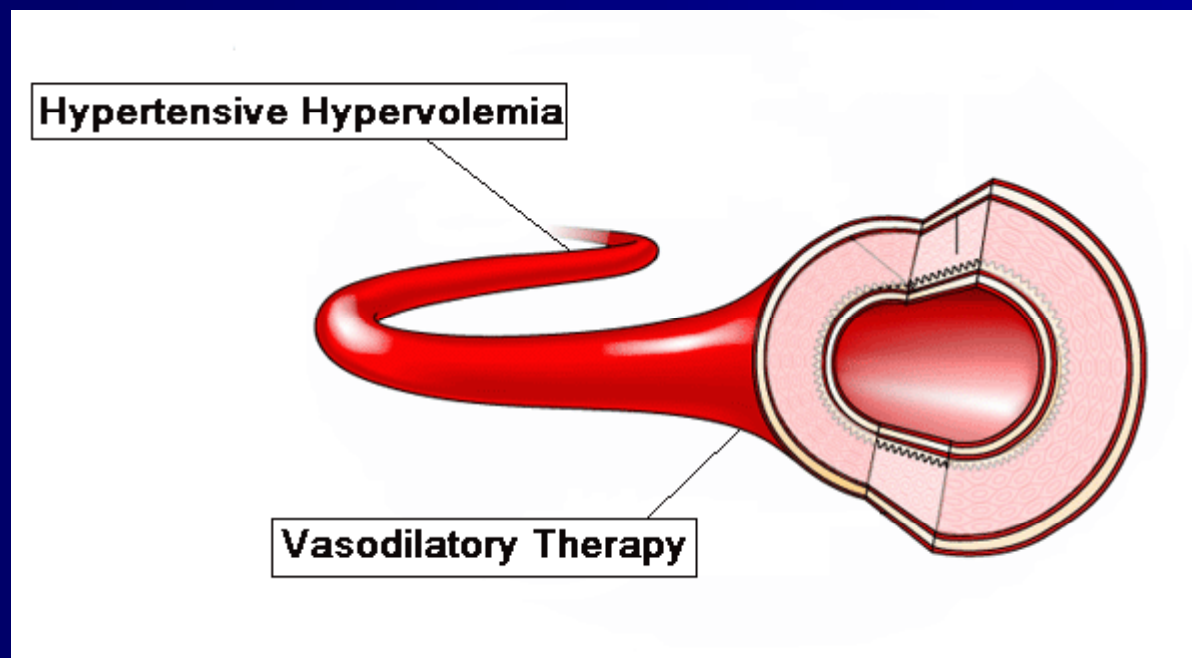
No Disclosures

# Background

- The standard of care for cerebral vasospasm has been hypertensive hypervolemic hemodilution (HHH) therapy in an attempt to increase cerebral blood flow, and calcium channel antagonists (CCA) as preventive or rescue therapy.
  - Nimodipine – intravenous, intra-arterial, oral
  - Verapamil – intra-arterial
  - Nicardipine – intravenous, intra-arterial, intracranial biocompatible controlled release systems
- However, continuous intravenous CCA have not been used as a therapeutic option at the onset of CV.

# The Big Idea

Would hypertensive hypervolemic therapy with a continuous intravenous infusion of nicardipine at the onset of cerebral vasospasm induce a progressive arterial vasodilatation resulting in a decrease in TCD velocities?



# Methods

- Retrospective study of a prospective, nonrandomized crossover feasibility protocol of HHVD vs hypertensive hypervolemia (HH) alone over 4 years (2005 – 2009)
- Daily Transcranial Doppler (TCD) mean velocities (MV) of the anterior and middle cerebral arteries were completed
- HH therapy began when TCD  $>120\text{cm/sec}$ , LR $>3$
- HH therapy was done for 48 hours
- Patients were crossed over from HH to HHVD if TCD velocities worsened despite HH therapy
- For HHVD, nicardipine was infused at 2mg/hr while SBP goals kept unchanged using norepinephrine
- The primary outcome was the rate in decline of TCD velocity
- Data was analyzed for progressive arterial dilation between the two therapies, incidence of rescue therapy, symptomatic versus asymptomatic vasospasm, DINDS, difference in rate of norepinephrine infusion, hypotension, and myocardial infarction (MI) defined as Troponin  $>5.0\text{ ng/mL}$

# Demographics

## ■ HHVD group\*

- 16 patients
- Fisher grade
  - Grade 3+4: 10
  - Grade 3: 5
  - Grade unknown: 1
- M:F 3:13
- Average age 47

## ■ HH group\*

- 20 patients
- Fisher grade
  - Grade 3+4: 14
  - Grade 3: 5
  - Grade 2: 1
- M:F 9:11
- Average age 51

\*There was no statistical difference between the two groups.

# Transcranial Doppler Velocities for the first 5 days

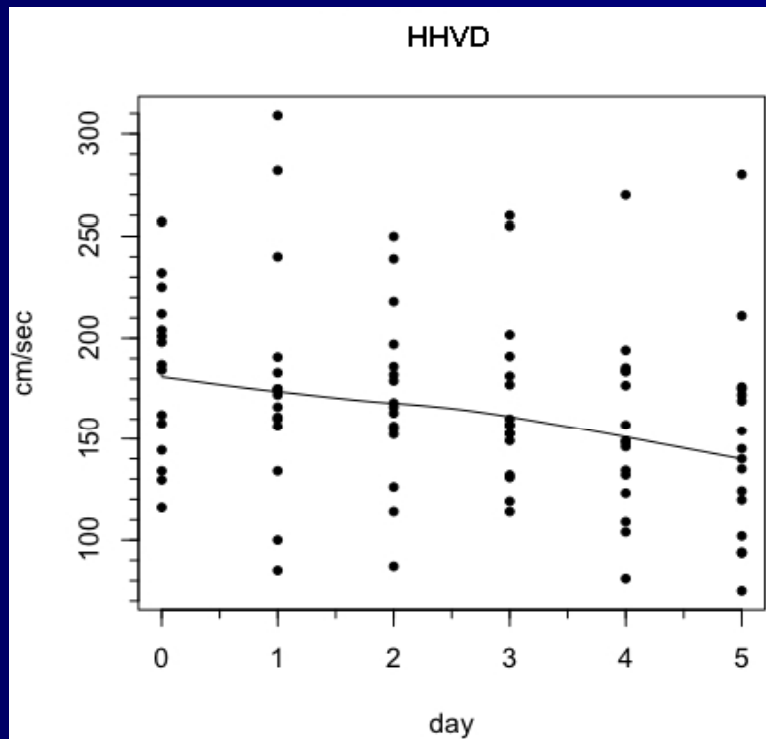


Figure 1: The first 5 days after the start of HHVD therapy

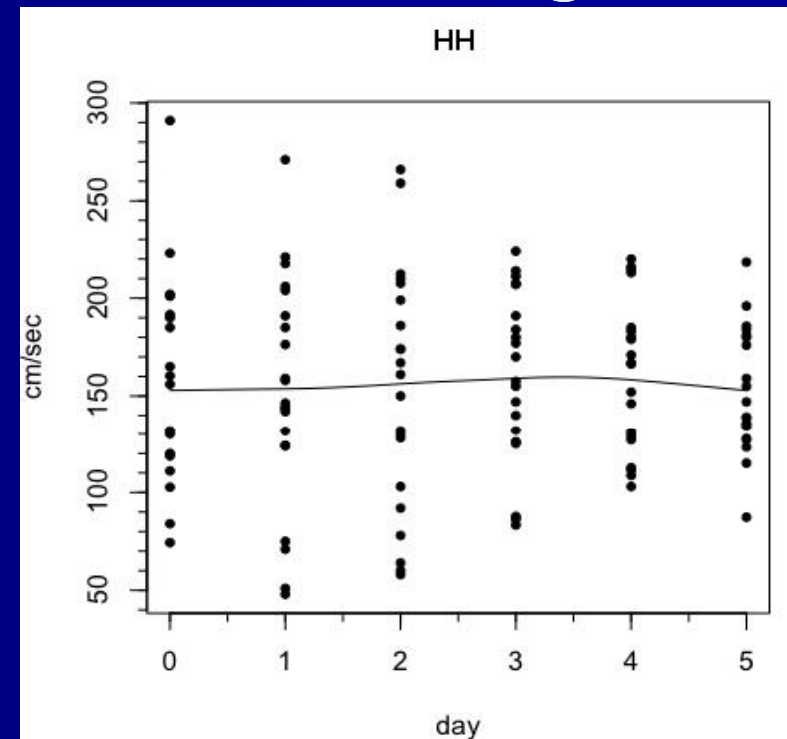


Figure 2: The first 5 days after the start of HH therapy alone.

On average, the start of HHVD therapy showed a progressive decline in mean velocity of 4.1 days sooner than HH therapy alone ( $p=0.012$ ). The rate of decline for HHVD was 6 cm/sec/day compared to 0 cm/sec/day in the HH group.

# Velocities > 180 and 200cm/sec

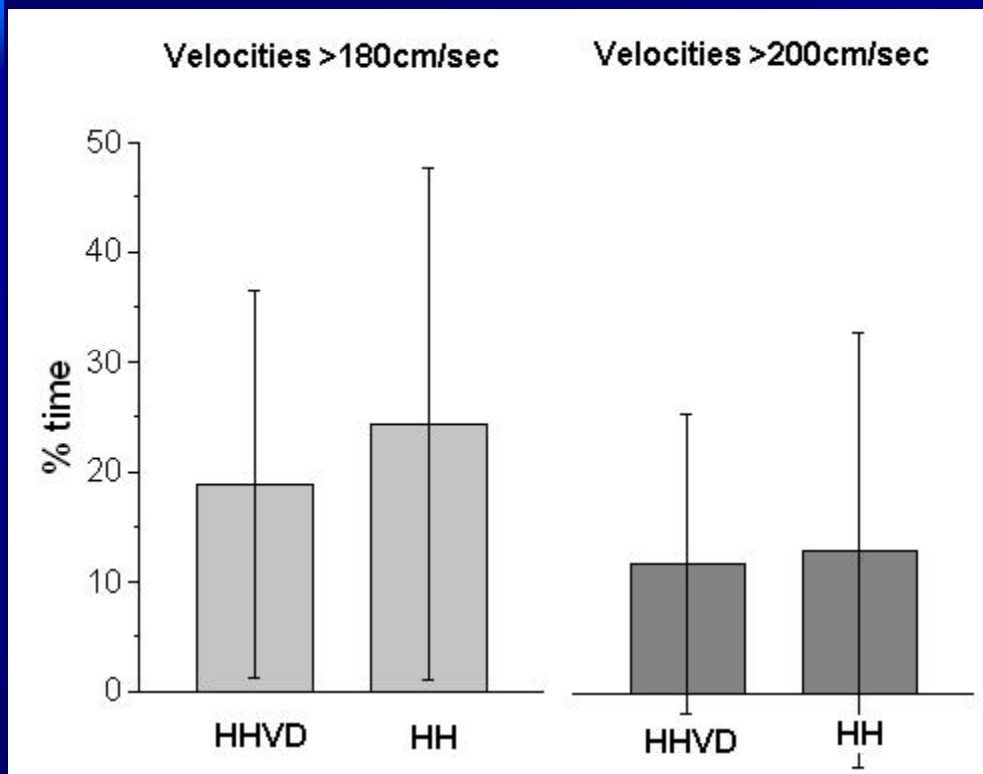


Figure 3: Showing the percentage of time mean velocities spent >180cm/sec and 200cm/sec for HHVD and HH groups. Velocities >180cm/sec for HHVD 18.92%, HH 24.36%,  $p=n.s.$  Velocities >200 for HHVD 11.85%, for HH 13.13%,  $p=n.s.$

# Rescue Therapy Between Groups

# IA rescue events during therapy

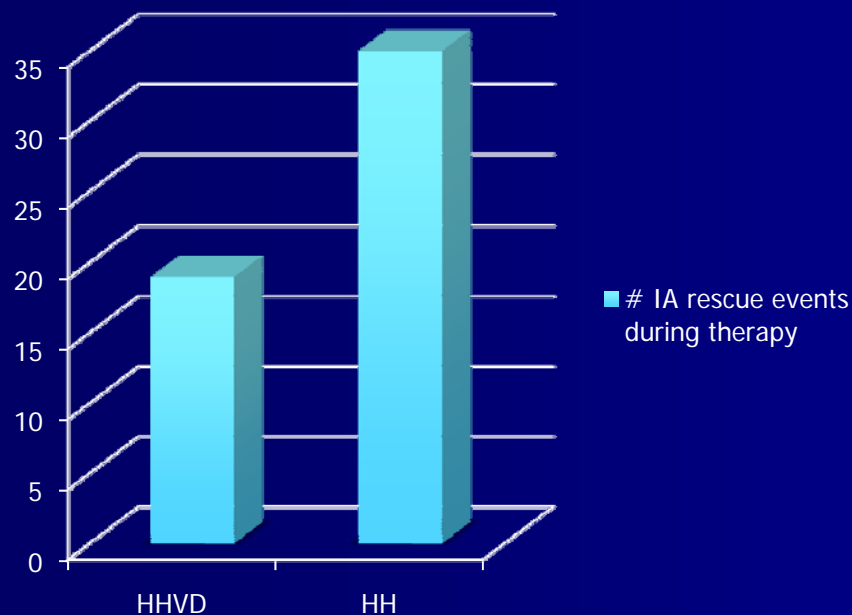
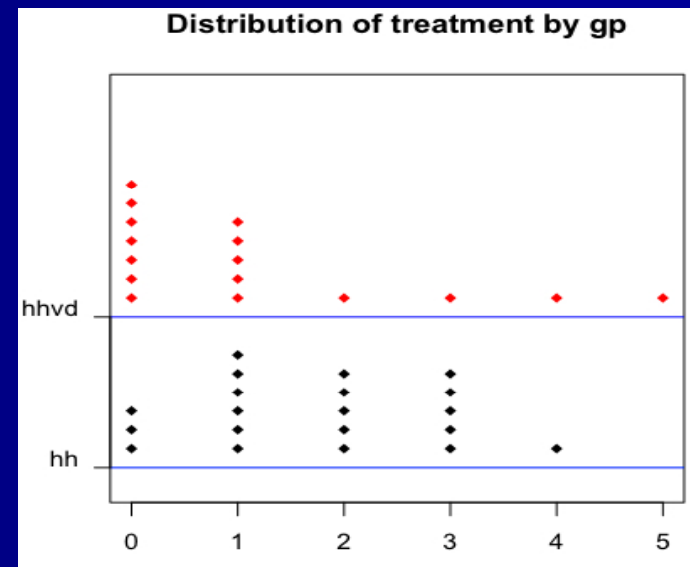


Figure 4: Frequency of rescue therapy between HHVD and HH groups. HH group required rescue therapy 35 times, while the HHVD group required treatment on 19 occasions.



# Systolic Blood Pressure Between the Two Groups

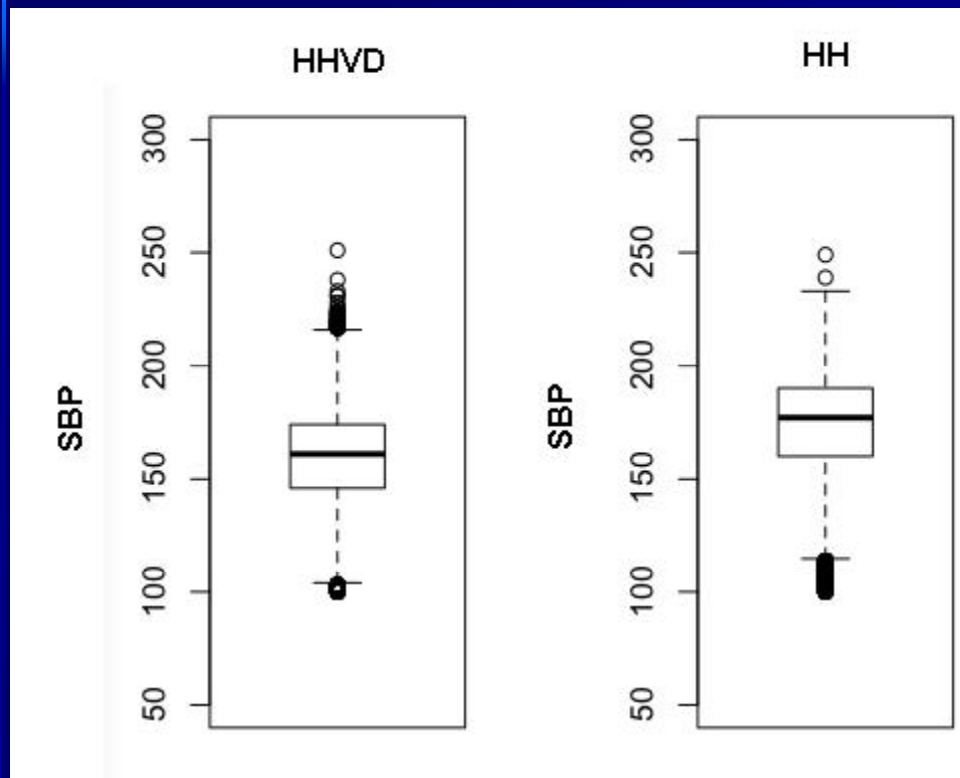
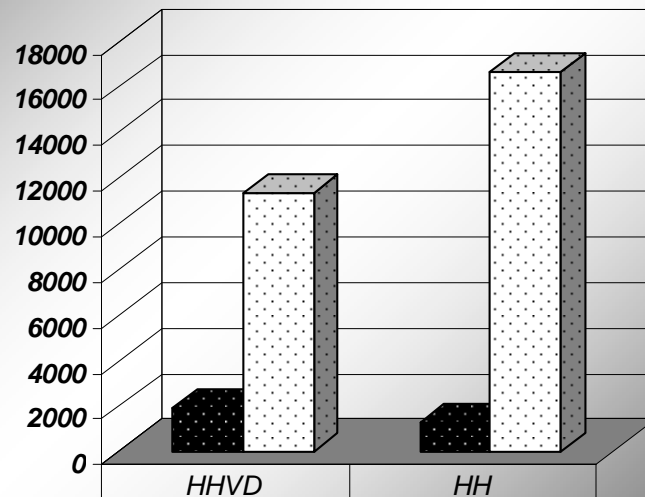


Figure 6: Systolic blood pressure (SBP) between the HHVD and HH groups. (HHVD vs HH: mean 161 vs 173 mmHg,  $p=0.024$ ).

# Incidence of inadvertent hypotension

## Events of SBP <140 mmHg

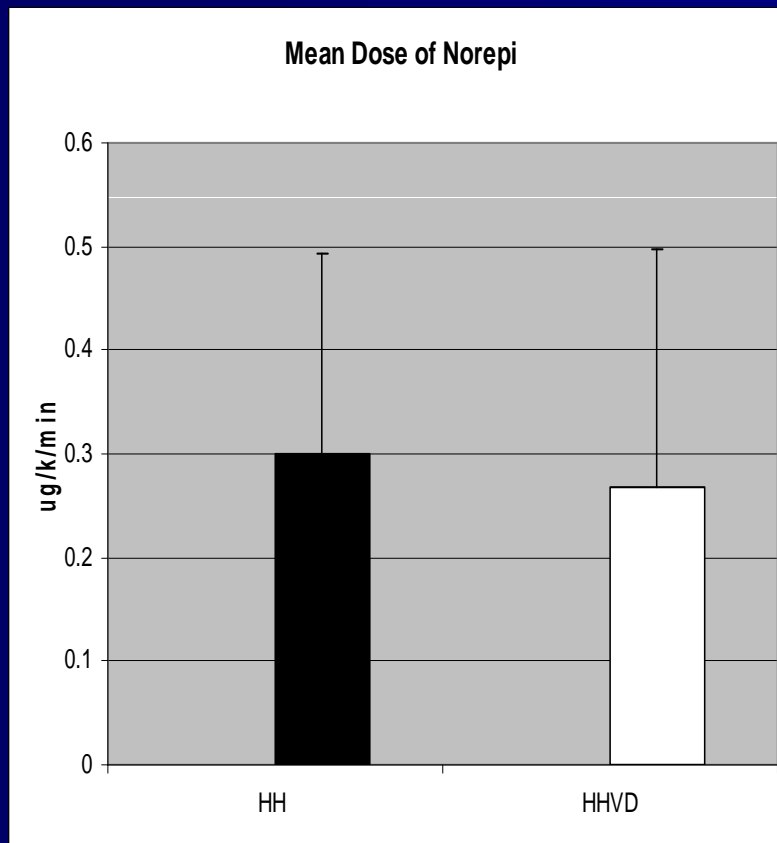
Number of Events SBP < 140 mmHg



■ SBP < 140	1934	1301
□ Total Measurements	11305	16609

Figure 8: Percentage of SBP <140 mmHg between HHVD and HH therapy. HHVD 17.10% vs HH 7.83% ( $p < 0.0001$ ; OR 2.42, 95% CI 2.25-2.61).

# Norepinephrine infusion



- On average, the HH group had a higher rate of norepinephrine infusion (0.300 vs 0.268 mcg/kg/min; SD=0.194 vs 0.230,  $p < 0.0001$ ).
  - However, analysis of variance yielded a statistically significant interaction between group, age, gender, and weight of  $p = 0.001$  for all variables.

- There was no difference between the two groups with regard to symptomatic or asymptomatic vasospasm, DINDS, or MI.

# Conclusion

- HHVD therapy showed a progressive decline in mean cerebral velocities of 6 cm/sec/day, with vasospasm ending 4.1 days sooner as compared to HH therapy alone.
- Furthermore, HHVD may reduce the need for rescue intra-arterial therapy. However, HHVD therapy was complicated by more hypotensive events and lower mean SBP. Larger studies are needed to confirm these results.

# References

- 1.Reddy P, Yeh YC. Use of injectable nicardipine for neurovascular indications. *Pharmacotherapy*. 2009 Apr;29(4):398-409.
- 2.Barth M, Thomé C, Schmiedek P, Weiss C, Kasuya H, Vajkoczy P. Characterization of functional outcome and quality of life following subarachnoid hemorrhage in patients treated with and without nicardipine prolonged-release implants. *J Neurosurg*. 2009 May;110(5):955-60.
- 3.Omeis I, Neil JA, Murali R, Abrahams JM. Treatment of cerebral vasospasm with biocompatible controlled-release systems for intracranial drug delivery. *Neurosurgery*. 2008 Dec;63(6):1011-9; discussion 1019-21.
- 4.Nogueira RG, Lev MH, Roccatagliata L, Hirsch JA, Gonzalez RG, Ogilvy CS, Halpern EF, Rordorf GA, Rabinov JD, Pryor JC. Intra-arterial nicardipine infusion improves CT perfusion-measured cerebral blood flow in patients with subarachnoid hemorrhage-induced vasospasm. *AJNR Am J Neuroradiol*. 2009 Jan;30(1):160-4. Epub 2008 Oct 22.
- 5.Kronvall E, Undrén P, Romner B, Säveland H, Cronqvist M, Nilsson OG. Nimodipine in aneurysmal subarachnoid hemorrhage: a randomized study of intravenous or peroral administration. *J Neurosurg*. 2009 Jan;110(1):58-63.
- 6.Hänggi D, Turowski B, Beseoglu K, Yong M, Steiger HJ. Intra-arterial nimodipine for severe cerebral vasospasm after aneurysmal subarachnoid hemorrhage: influence on clinical course and cerebral perfusion. *AJNR Am J Neuroradiol*. 2008 Jun;29(6):1053-60.
- 7.Mazumdar A, Rivet DJ, Derdeyn CP, Cross DT 3rd, Moran CJ. Effect of intraarterial verapamil on the diameter of vasospastic intracranial arteries in patients with cerebral vasospasm. *Neurosurg Focus*. 2006 Sep 15;21(3):E15.
- 8.Kasuya H, Onda H, Sasahara A, Takeshita M, Hori T. Application of nicardipine prolonged-release implants: analysis of 97 consecutive patients with acute subarachnoid hemorrhage. *Neurosurgery*. 2005 May;56(5):895-902.
- 9.Shibuya M, Suzuki Y, Enomoto H, Okada T, Ogura K, Sugita K. Effects of prophylactic intrathecal administrations of nicardipine on vasospasm in patients with severe aneurysmal subarachnoid haemorrhage. *Acta Neurochir (Wien)*. 1994;131(1-2):19-25.
- 10.Gilsbach JM, Reulen HJ, Ljunggren B, Brandt L, von Holst H, Mokry M, von Essen C, Conzen MA. Early aneurysm surgery and preventive therapy with intravenously administered nimodipine: a multicenter, double-blind, dose-comparison study. *Neurosurgery*. 1990 Mar;26(3):458-64.
- 11.Grotenhuis JA, Bettag W. Prevention of symptomatic vasospasm after SAH by constant venous infusion of nimodipine. *Neurol Res*. 1986 Dec;8(4):243-9.
- 12.Philippon J, Grob R, Dageou F, Guggiari M, Rivierez M, Viars P. Prevention of vasospasm in subarachnoid haemorrhage. A controlled study with nimodipine. *Acta Neurochir (Wien)*. 1986;82(3-4):110-4.
- 13.Haley EC Jr, Kassell NF, Torner JC, Truskowski LL, Germanson TP. A randomized trial of two doses of nicardipine in aneurysmal subarachnoid hemorrhage. A report of the Cooperative Aneurysm Study. *J Neurosurg*. 1994 May;80(5):788-96.
- 14.Haley EC Jr, Kassell NF, Torner JC. A randomized trial of nicardipine in subarachnoid hemorrhage: angiographic and transcranial Doppler ultrasound results. A report of the Cooperative Aneurysm Study. *J Neurosurg*. 1993 Apr;78(4):548-53.
- 15.Haley EC Jr, Kassell NF, Torner JC. A randomized controlled trial of high-dose intravenous nicardipine in aneurysmal subarachnoid hemorrhage. A report of the Cooperative Aneurysm Study. *J Neurosurg*. 1993 Apr;78(4):537-47.